

An innovative device for fractional CO₂ laser resurfacing: a preliminary clinical study.

Daniel A. Cassuto, Luca Scrimali, Paolo Siragò

Department of Plastic Surgery, University of Catania, Catania, Italy

Background

CO₂ laser resurfacing is a powerful tool for the treatment of several skin conditions such as fine and coarse wrinkles, scars of various origin, uneven pigmentation, dilated pores et al. Some major drawbacks have progressively limited its use: the need for effective anaesthesia, the downtime, the risk of dyspigmentation and scarring, the need for intensive postoperative care, the long-lasting erythema and the long avoidance of sun exposure.

Fractional photothermolysis was introduced by Huzaira and colleagues in 2003. It was developed to overcome the above mentioned drawbacks in the treatment of photo damaged skin. Fractional Laser Resurfacing with the midinfrared lasers uses an invisible laser beam which is strongly absorbed by water, in order to reverse the effects of skin aging and scarring. Near infrared wavelengths (Fraxel, Reliant, 1550nm; Lux 1540, Palomar) cause significant pain and require some form of anaesthesia. This is a time consuming and costly aspect. Another disadvantage for the operator is that most of these devices are only capable of performing this kind of treatment. The use of ablative lasers in a fractional mode was introduced in 2006. The lesser depth of immediate tissue necrosis, in comparison to the midinfrared wavelengths, together with the possibility of further heat deposition in the dermis, significantly reduces the pain caused by the procedure, without decreasing its efficacy. A new CO₂ laser (Active FX, Lumenis, 10600nm) with less penetration was shown to be more tolerable, but the 1.3 mm spot still makes some local anaesthesia and/or cooling necessary. The spot distribution is not distributed as uniformly as with the midinfrared devices. A more recent CO₂ laser system (Slim Evolution, Lasering,) with a microspot system (300µ) fractional modality (Mixto SX) has been developed with a new scanning algorithm that keeps the longest possible interval between two adjacent spots, in order to minimize the heat accumulation around the treated areas. This is supposed to significantly reduce the pain during the procedure. An overview of the characteristics of several fractional devices is shown in table number 1.

Table 1. Overview of infrared fractional lasers and their features

Laser Feature	Mixto SX Lasering	Encore® Lumenis	Pixel® Alma Laser	Lux 1540 Palomar	Affirm® Cynosure	Fraxel® Reliant
Wavelength	10.600 nm	10.600 nm	2940 nm	1540 nm	1440 nm	1550nm
Type of emission	Continuous\Pulsed	Pulse	Pulse	Pulse	Pulse	Continuous
Beam Spot size	0.3 mm	1.3 mm	0.7 mm	0.2- 0.3mm	N.A.	N.A.
Scanned area	20x20 mm	14x14 mm	11x11 mm	10-15 mm	10 mm	N/A
Scanner	Yes	Yes	No	Yes	No	Yes
Mode	Ablative	Ablative	Ablative	Non ablative	Non ablative	Non ablative

Objective

A new CO₂ laser system (Slim Evolution, Lasering, Modena, Italy) with a unique fractional modality (Mixto SX), added to a high speed scanner is tested as a tool for skin rejuvenation. It will be tested to evaluate its efficacy and tolerability as a tool for skin rejuvenation without any form of anaesthesia or cooling.

Materials and Methods

The Mixto SX™ system (Lasering srl, Modena, Italy) is a fractional CO₂ laser equipped with a new generation Computerized Pattern Generator (CPG). Its recently developed algorithm allows the 300µ beam to be delivered at such intervals that greatly increase its tolerability. Its pattern results in a precise beam delivery over the treated area. The operator can chose particular scarred\sun damaged areas for treatment as needed. It can perform traditional and fractional resurfacing at depths ranging from 20 to 500 microns, treating 20% or 100% of the scanned area. The traditional single beam is also available for vaporizing solid lesions or cutting purposes. A series of 24 consecutive patients (skin types II-IV) has been treated with one pass of the above mentioned fractional CO₂ laser (11 faces, 5 necks, 8 hands). No anaesthesia or skin cooling was used. The power used was between 8 and 10 watts, with SX index values of 6-8, according to the indication and to patient tolerance. A single pass was done over the whole area. The postoperative management included a thermal water based cream (Cicalfate, Avène, France) and free use of makeup. Pain tolerance was measured with a 0-5 score (see table 2). Digital clinical microphotography was used before and 3 months after treatment, in order to assess the results, by an independent evaluator according to the scale shown in table 3. Satisfaction questionnaires were filled by all patients according to how strongly they would recommend the treatment to their friends. In order to eliminate the bias in satisfaction questionnaires (see table 4) all patients were charged for the treatments.

Table 2: Pain Score Scale.

Score	0	1	2	3	4	5
Description	Not felt	Barely felt	Easily tolerable	Tolerable	Barely Tolerable	Unbearable

Table 3: Criteria for evaluation of the results by digital photography.

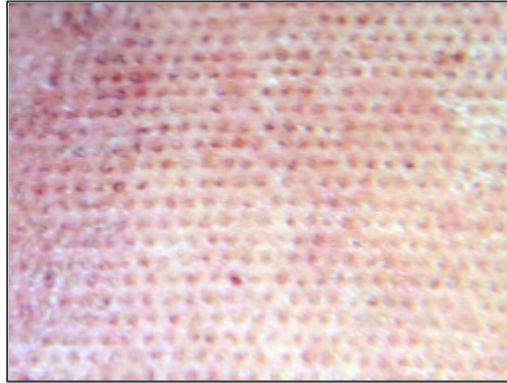
Score	1	2	3	4
Improvement (%)	0-25	25-50	50-75	75-100

Table 4: Subjective satisfaction criteria

Score	1	2	3	4
Patient's recommendation	Not at all	Uncertain	Positive	High

Results

All patients showed significant improvement in skin texture and colour after one single treatment. The average improvement score given by the independent observer was 3.83. Postoperative undesired effects were immediate erythema and swelling that subsided within 24 hours. Fine pinpoint microcrusting (as shown in picture number 1) occurred in all cases and resolved within one week.

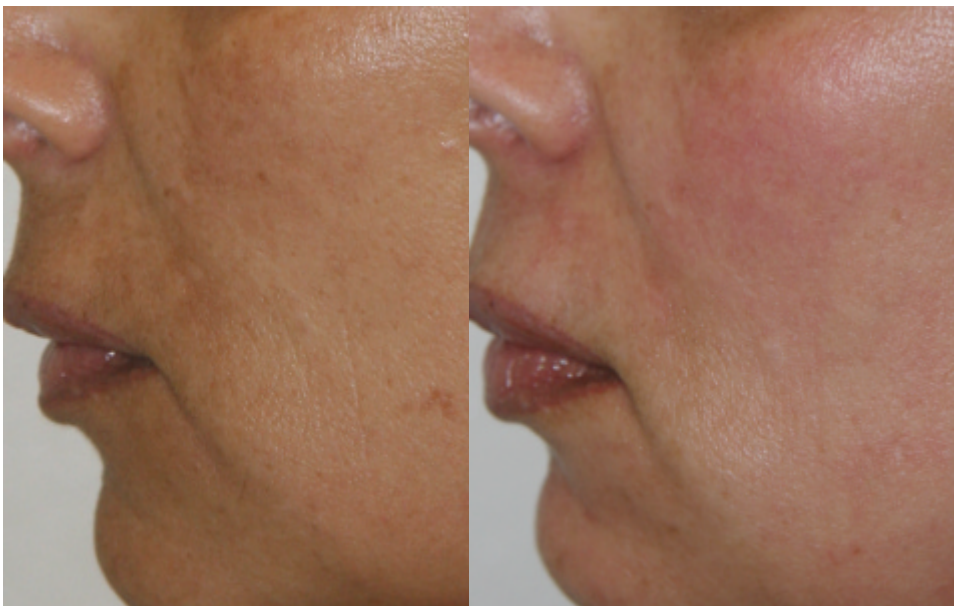

Picture 1. Highly magnified appearance of the microcrusting 48 hours after treatment. Each microcrust has a 300 μ diameter.

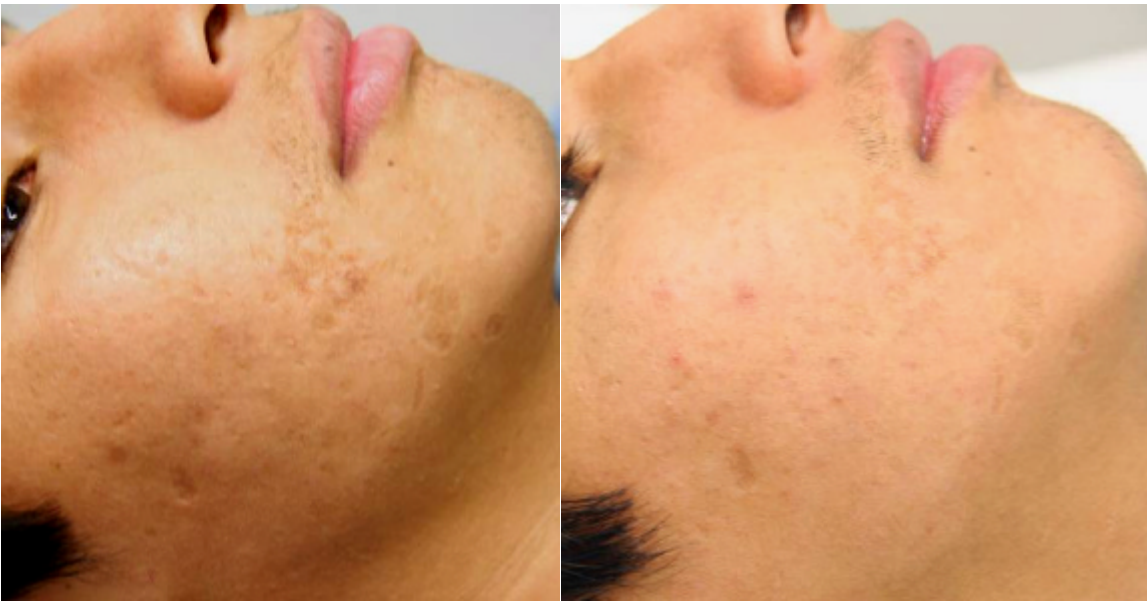With camouflage it looked like an exaggerated tan and was well tolerated. All patients tolerated the treatment sessions. The mean pain score was 1.8 (score 2=easily tolerated).

All patients expressed almost unanimously full satisfaction from the laser treatment (mean satisfaction score was 3.958). No drop-outs were observed. Postoperative undesired effects were immediate erythema and mild swelling that subsided within 48 hours. With camouflage these effects looked like a suntan and were well tolerated with no downtime. No long term side effects were observed after 6 months of follow up.

Some examples of the results are visible pictures number 2 and 3.



Picture 2: A 41 ys old patient with a mediterranean skin and moderate sun damage. Left-before treatment. Right-3 months after treatment. Notice the improvement in skin texture and colour. The fine wrinkles are almost erased from the cheek.



Picture 3: a 19 ys old Hispanic patient with hyperpigmented severe acne scarring. Left-before treatment. Right- 3 months after treatment (2 sessions, 1 month interval). The improvements in skin colour and scar remodelling are visible.

Discussion

Like other ablative fractional lasers, the Mixto SX™ showed to be more tolerable than the midinfrared devices, due to the deeper penetration of the latter. However, this did not result in a lesser efficacy, due to the fact that deep tissue irreversible damage is not necessary in order to stimulate rejuvenation by shrinkage (immediate) and new collagen formation (after 6-12 weeks). This effect is readily achieved by the lower SX indexes that cause a further heat delivery after the initial ablation. The depth of this ablation can be regulated by varying the power i.e. the watts. This versatility is quite promising, as it allows the operator to adjust the settings according to the different areas of the body, as skin thickness may vary from 150 μ , as in an aged lid, to a few millimeters on the forehead. Alternatively, the operator can make an overlapping scanned spot with a 45° angle of rotation, in order to achieve a microspot density of about 40%. This technique is particularly useful when treating areas with more intense photoaging (senile stains, deeper wrinkles) without recurring to more aggressive settings that would increase the pain. A 1-2 weeks lasting localized slight erythema should be expected in these areas. Solid benign lesions such as skin tags, seborrheic keratoses etc, can be ablated during the same treatment. Switching to a single beam emission for bloodless ablation or incision is done through the touch screen in 3 seconds, without changing the handpiece. The comparison to other fractional devices is shown in table 5.

Table 5. Overview of the treatment features of different fractional devices.

	Mixto SX Lasering	Encore® Lumenis	Pixel® Alma Laser	Lux 1540 Palomar	Affirm® Cynosure	Fraxel® Reliant
Time per session (total face) including immediate pre-post treatments	20 min	80 min	20 min	80 min	80 min	120 min
Sessions	1	1	1	4	4	4
Anaesthesia	No	Topical	No	Topical + Coolant	Topical + Coolant	Topical + Coolant
Side effects, post treatment	Erythema	Erythema	Erythema	Erythema+ Edema	Erythema+ Edema	Erythema+ Edema
Downtime (face)	4/6 d	4/6 d	4/6 d	6/8 d	6/8 d	6/8 d
Downtime (décolleté & hands)	7/10 d	7/10 d	7/10 d	10/12 d	10/12 d	10/12 d
Tightening	Yes	Yes	Yes	No	No	No

Eliminating the need for anaesthetic creams, chromophore gels and other water-based preparations will ensure that the water content of the skin is not altered before treatment. This is particularly important when using infrared wavelengths that are mainly absorbed by water (Peter Bjerring, personal communication) as in fractional resurfacing and photothermolysis.

Tips and tricks

The following advices should be useful for those who approach the first treatments with the Mixto SX™. Topical anaesthesia is not required for most patients. This should be discussed with patient prior to treatment. Avoid premenstrual days.

Wash thoroughly and let the skin dry before treatment.

Cover the patient's eyes with non reflecting protective goggles or water-soaked gauze.

Treatment is safe for the face, neck, chest and hands.

Initial settings are power at 8 watts and index at 8. The patient will not experience any discomfort at this "soft" setting.

Treatment of wrinkles – Power setting remains at 8 watts. The index setting will vary according to skin type and depth of wrinkles. Reduce the index setting to increase the exposure time and spot penetration. The new index setting is when the patient feels bearable discomfort but no pain. For treatment of deeper wrinkles prescribe an oral pain killer 1 hour prior to the procedure. This will enable the patient to sustain a lower SX index.

Treatment of acne scars – Index setting remains at 8. The power setting will vary according to skin type and severity of the acne scars. Increase the power setting until the desired effect on tissue is achieved. The patient should feel no pain. For treatment of deeper scars prescribe an oral pain killer 1 hour prior to the procedure. This will enable the patient to sustain a higher power.

Treatment area – the treatment area can be adjusted from 6x6mm to 20x20mm with increments of 2mm.

After fractional resurfacing, the laser can be switched to traditional CO2 mode for ablation of skin growths (e.g. skin tags, seborrheic keratoses etc.) or to traditional resurfacing mode in selected areas.

Post treatment - do not wipe the treated area. The eschar will promote the healing process. The patient will experience a burning sensation on the skin that lasts between 30 minutes and 3 hours. Apply a fragrance- and preservative-free moisturizer to the treated area. After one to two days, the erythema will be replaced by a progressively darkening sun-tanned look. At this point, makeup can be applied.

Expected downtime – Face up to 5 days

Neck up to 7 days,

Chest and Hands up to 10 days

Superficial wrinkles and skin defects usually disappear after one session. Deeper wrinkles and acne scars may require two or three sessions, spaced one month apart.

Conclusions: The Mixto SX™ is an effective and safe tool for skin rejuvenation by fractional laser resurfacing. Its versatility allows the operator to perform minimally invasive treatments, together with more aggressive resurfacing and or tissue ablation if needed. The remarkable tolerability makes its acceptance by patients easier and eliminates the need for cumbersome and time consuming cooling or anaesthetic procedures. The results are reproducible without need for any gel or other substance to be applied. Some tips are available in order to optimize the results.

References

1. Shook BA, Hruza GJ. Periorbital ablative and nonablative resurfacing. *Facial Plast Surg* Clint North Am. 2005 Nov; 13(4):571-82, vii. Review.PMID: 16253844.
2. Apfelberg DB. The Ultrapulse carbon dioxide laser with computer pattern generator automatic scanner for facial cosmetic surgery and resurfacing. *Ann Plast Surg* 1996; 36:522-529.
3. Fitzpatrick RE, Goldman MP, Sautr NM, Tope WD. Pulsed carbon dioxide laser resurfacing of photo-aged facial skin. *Arch Dermatol* 1996; 132:395-402.
4. Alster TS: Cutaneous resurfacing with CO2 and erbium: YAG lasers: preoperative, intraoperative, and postoperative considerations. *Plast Reconstr Surg* 1999 Feb; 103(2): 619-32.
5. Walsh JT Jr, Flotte TJ, Anderson RR: Pulsed CO2 laser tissue ablation: effect of tissue type and pulse duration on thermal damage. *Lasers Surg Med* 1988; 8(2): 108-18.
6. West TB, Alster TS: Effect of pretreatment on the incidence of hyperpigmentation following cutaneous CO2 laser resurfacing. *Dermatol Surg* 1999 Jan; 25(1): 15-7.
7. Alster TS: Side effects and complications of laser surgery. In Alster TS: *Manual of Cutaneous Laser Techniques*, ed 2. Philadelphia, Lippincott 2000; pp 175-187.